

5-1-2023

## Targeted alveo-pleural fistula endobronchial valve treatment using ventilation scintigraphy

Calvin Sidhu  
*Edith Cowan University*

Shoba Ratnagobal

Rajesh Thomas

Gary Y.C. Lee

Enya Drudy

*See next page for additional authors*

Follow this and additional works at: <https://ro.ecu.edu.au/ecuworks2022-2026>



Part of the [Rehabilitation and Therapy Commons](#)

---

[10.1002/rcr2.1146](https://doi.org/10.1002/rcr2.1146)

Sidhu, C., Ratnagobal, S., Thomas, R., Lee, G. Y., Drudy, E., & Francis, R. J. (2023). Targeted alveo-pleural fistula endobronchial valve treatment using ventilation scintigraphy. *Respirology Case Reports*, 11(5), Article e01146.

<https://doi.org/10.1002/rcr2.1146>

This Journal Article is posted at Research Online.

<https://ro.ecu.edu.au/ecuworks2022-2026/2425>

---

**Authors**

Calvin Sidhu, Shoba Ratnagobal, Rajesh Thomas, Gary Y.C. Lee, Enya Drudy, and Roslyn J. Francis

## CASE REPORT

# Targeted alveo-pleural fistula endobronchial valve treatment using ventilation scintigraphy

Calvin Sidhu<sup>1</sup> | Shoba Ratnagopal<sup>2</sup> | Rajesh Thomas<sup>3</sup> | Gary Y. C. Lee<sup>3,4</sup> | Enya Drudy<sup>2</sup> | Roslyn J. Francis<sup>2</sup>

<sup>1</sup>School of Medical and Health Sciences, Edith Cowan University, Perth, Western Australia, Australia

<sup>2</sup>Nuclear Medicine Department, Sir Charles Gairdner Hospital, Perth, Western Australia, Australia

<sup>3</sup>Respiratory Department, Sir Charles Gairdner Hospital, Perth, Western Australia, Australia

<sup>4</sup>School of Medicine, University of Western Australia, Perth, Western Australia, Australia

## Correspondence

Calvin Sidhu, Sir Charles Gairdner Hospital, B Block, Hospital Ave, Nedlands, Perth, 6009 WA, Australia.

Email: calvinjit.sidhu@health.wa.gov.au

Associate Editor: Phan Nguyen

## Abstract

Persistent air-leaks can be difficult to localize in radiology. Bronchoscopic management of air-leaks requires identification of the leak's location to allow suitable targeted treatment. One-way endobronchial valves have become a suitable option for persistent air-leaks. In this report, a combination scintigraphy and one-way endobronchial valve treatment successfully resolved a persistent air-leak.

## KEYWORDS

alveo-pleural fistula, bronchoscopy, endobronchial, interventional, valve

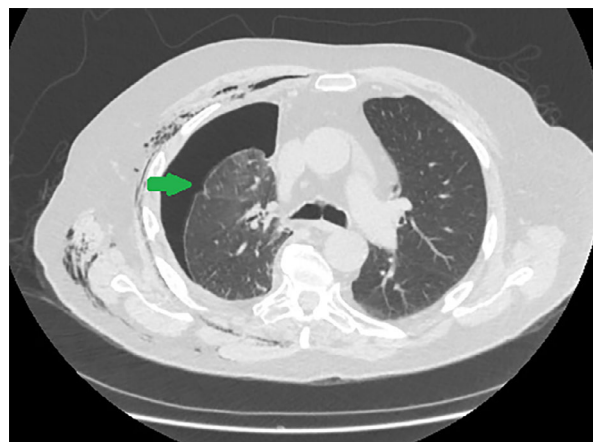
## INTRODUCTION

Persistent air-leaks are pneumothoraces that continue for an extended period of time, usually >5 days.<sup>1</sup> These leaks can be classified into broncho-pleural (BPF) or alveolar-pleural fistulas (APF) and are commonly caused by chronic lung disease, trauma or are iatrogenic (bronchoscopic lung volume reduction, transthoracic lung biopsies, lung resections or mechanical ventilation).<sup>1</sup> Although the majority of air-leaks resolve with time, intervention can avoid prolonged hospitalization and patient deconditioning. Air leak management consists of a variety of techniques but the crucial initial step of localization can be difficult.

## CASE REPORT

A 79-year male underwent thoracoscopy for investigation of a right pleural effusion, due to background asbestos exposure and indeterminate pleural fluid cytology. Thoracoscopy revealed diffuse visceral and parietal nodularity, with thickened visceral pleura after 2000 mL of fluid was drained. Pleural biopsies performed from the parietal pleura diagnosed biphasic

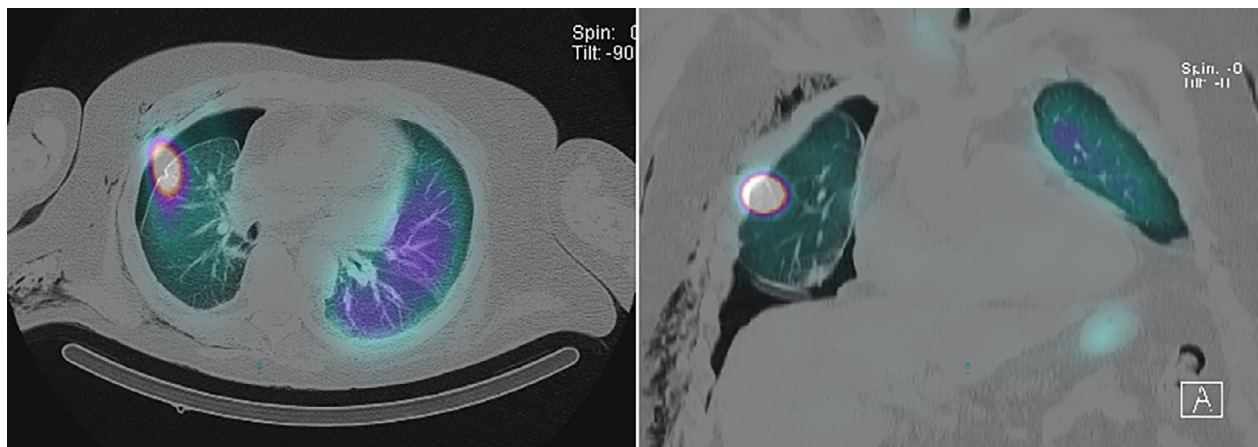
malignant pleural mesothelioma. There were no intra-procedural complications, however continuous bubbling (Cerfolio Grade 4) via intercostal catheter (ICC) in-situ post-thoracoscopy was consistent with an alveolar-pleural fistula.<sup>1</sup>



**FIGURE 1** Axial chest computed tomography image showing right pleural abnormality (green arrow), with the presence of pneumothorax and subcutaneous emphysema

This is an open access article under the terms of the [Creative Commons Attribution-NonCommercial-NoDerivs](https://creativecommons.org/licenses/by-nc-nd/4.0/) License, which permits use and distribution in any medium, provided the original work is properly cited, the use is non-commercial and no modifications or adaptations are made.

© 2023 The Authors. *Respirology Case Reports* published by John Wiley & Sons Australia, Ltd on behalf of The Asian Pacific Society of Respiratory.



**FIGURE 2** SPECT-CT coronal and axial images showing area of inhaled Technegas tracer deposition within the right upper lobe visceral pleura

To possibly assist in fistula localization, a ventilation scintigraphy (VS) scan was performed with the patient's consent. The patient inhaled Technegas (Cyclomedica Pty Ltd.), a suspension of carbon particles labelled with  $^{99m}\text{Tc}$ . Dynamic planar images and single photon emission computed tomography (SPECT-CT) was performed. The images demonstrated focal tracer deposition corresponding with a possible pleural defect in the right upper lobe seen on computed tomography (CT) images (Figures 1 and 2). Due to non-expandable lung, right oblique and horizontal fissures were difficult to visualize to determine fissural integrity.

Flexible bronchoscopy was performed under general anaesthesia and spontaneous ventilation. Balloon occlusion of RB3 resulted in visualized reduction of the air-leak. Two endobronchial valves (EBV) were deployed in 2 RB3 subsegments. Due to continued bubbling 7 days post-EBV deployment, surgical pleurodesis was attempted but also unsuccessful. Visceral pleural defect was not visualized intra-operatively. Repeat bronchoscopy was performed to completely obstruct the right-upper lobe using additional EBV deployments in RB1 and RB2 segments. Air-leak ceased, but the patient was then diagnosed with pleural infection. He was discharged home 8 days later after removal of ICC and continued ambulatory pleural infection treatment. Review until 6 weeks later demonstrated no air-leak recurrence.

## DISCUSSION

We report on a case of successful alveolar-pleural fistula visualization by ventilation scintigraphy in response to endobronchial valve treatment at the fistula's radiological location.

APF can be managed using bronchoscopic, pleural and surgical techniques. Bronchoscopic APF management options include use of endobronchial spigots, tissue adhesives, airway stents and one-way endobronchial valves.<sup>1</sup> Bronchoscopic management begins with the determination of sub-lobe or lobar segments associated with the fistula,

using balloon occlusion and re-assessment of air-leak rate. Endobronchial or intrapleural methylene blue can also be used for APF localization. Determination of air-leak site can be inaccurate due to patient positioning, respiratory effort, size of defect or dependence on subjective assessment of the rate of air-leak, affecting successful APF closure as in the first bronchoscopy in our case.

Radiology can also assist in APF localization. CT can occasionally show a clear defect in the visceral pleura that is then confirmed by bronchoscopic balloon occlusion. If no obvious radiological defect is present, then bronchoscopic procedural time is prolonged as the APF location has to be determined segment by segment.

The potential for VS to determine sites of active or resolved alveolar and bronchial air-leaks has been shown in several case series. One showed VS-determined active alveolar and broncho-pleural fistulas that were targeted for surgical treatment, with subsequent resolution on repeated scintigraphy.<sup>2</sup> VS was also able to detect and confirm successful bronchoscopic treatment of BPFs using septal occluders.<sup>3</sup> A prospective series trialed Xenon-133 ( $^{133}\text{Xe}$ ), used in other institutions instead of Technegas, and also showed successful fistula detection.<sup>4</sup> It was suggested  $^{133}\text{Xe}$  could be more suitable in patients with obstructive lung disease due to less tracheo-bronchial deposition.<sup>4</sup> The mainstay technology of SPECT-CT is to localize tracer deposition, seen in others and our case, although the reason for this deposition is unclear.

Initial EBV-occlusion of the RB3 segment in our case, where the air-leak corresponded to was likely unsuccessful due to collateral ventilation through the remaining right upper lobe *intra-lobe* segments. Successful use of EBVs for lung volume reduction requires lack of *inter-lobe* collateral ventilation. Use of available complementary systems to quantify collateral ventilation and rate of air-leak could be combined with VS to further improve precision of isolating the leak site both before and during bronchoscopy, with the potential advantage of limiting number of lung segments that need to be occluded.<sup>5</sup>

Ventilation scintigraphy has been available for many years, however this utility to target air-leak valve treatments could be a promising adjunct for the difficult clinical scenario of alveolar-pleural fistula localisation. Benefits could include expedited and accurate fistula detection, shortened procedural times, shorter hospital stays with resultant cost savings but requires much more study.

### AUTHOR CONTRIBUTIONS

Calvin Sidhu—(i) the conception or design of the work, the acquisition, analysis or interpretation of data for the work; (ii) drafting the work or revising it critically for important intellectual content; and (iii) final approval of the version to be published. Shoba Ratnagopal—(i) the conception or design of the work, the acquisition, analysis or interpretation of data for the work; (ii) drafting the work or revising it critically for important intellectual content; and (iii) final approval of the version to be published. Rajesh Thomas—(i) the conception or design of the work, the acquisition, analysis or interpretation of data for the work; (ii) drafting the work or revising it critically for important intellectual content; and (iii) final approval of the version to be published. Gary Y. C. Lee—(i) the conception or design of the work, the acquisition, analysis or interpretation of data for the work; (ii) drafting the work or revising it critically for important intellectual content; and (iii) final approval of the version to be published. Enya Drudy—(i) the conception or design of the work, the acquisition, analysis or interpretation of data for the work; (ii) drafting the work or revising it critically for important intellectual content; and (iii) final approval of the version to be published. Roslyn J. Francis—(i) the conception or design of the work, the acquisition, analysis or interpretation of data for the work; (ii) drafting the work or revising it critically for important intellectual content; and (iii) final approval of the version to be published.

### ACKNOWLEDGMENTS

Dr Niranjan Setty, Nurse Sue Morey, Nurse Siobhan Dormer, Nurse Chloe Charlesworth. Dr Peter Swift & Sir Charles Gairdner Hospital Nuclear Medicine Department.

### CONFLICT OF INTEREST STATEMENT

Gary YC Lee is an Editorial Board member of Respiratory Case Reports and a co-author of this article. They were

excluded from all editorial decision-making related to the acceptance of this article for publication. The other authors have no conflicts of interest to declare.

### DATA AVAILABILITY STATEMENT

Data available on request from the authors.

### ETHICS STATEMENT

The authors declare that appropriate written informed consent was obtained for the publication of this manuscript and accompanying images.

### ORCID

Calvin Sidhu  <https://orcid.org/0000-0002-4574-8157>

Gary Y. C. Lee  <https://orcid.org/0000-0002-0036-511X>

### REFERENCES

1. Dugan KC, Laxmanan B, Murgu S, Hogarth DK. Management of persistent air leaks. *Chest*. 2017;152(2):417–23.
2. Nielsen KR, Blake LM, Mark JB, DeCampi W, McDougall IR. Localization of bronchopleural fistula using ventilation scintigraphy. *J Nucl Med*. 1994;35(5):867–9.
3. Ono CR, Tedde ML, Scordamaglio PR, Buchpiguel CA. Pulmonary inhalation-perfusion scintigraphy in the evaluation of bronchoscopic treatment of bronchopleural fistula. *Radiol Bras*. 2018;51(6):385–90.
4. Raja S, Rice TW, Neumann DR, Saha GB, Khandekar S, MacIntyre WJ, et al. Scintigraphic detection of post-pneumectomy bronchopleural fistulae. *Eur J Nucl Med*. 1999;26(3):215–9.
5. Tian Q, Qi F, An Y, Liu XC, Chen LA. Using the chartis system to selectively target a lung segment with a persistent air leak. *Eur Respir J*. 2013;41(6):1461–3.

**How to cite this article:** Sidhu C, Ratnagopal S, Thomas R, Lee GYC, Drudy E, Francis RJ. Targeted alveo-pleural fistula endobronchial valve treatment using ventilation scintigraphy. *Respirology Case Reports*. 2023;11:e01146. <https://doi.org/10.1002/rcr2.1146>